

**Fluorescent light energy combined with systemic isotretinoin:  
A 52 week follow-up evaluating efficacy and safety in  
treatment of moderate-severe acne**

Journal:	Clinical Case Reports
Manuscript ID:	CCR3-2020-06-0931
Wiley - Manuscript type:	Case Report
Date Submitted by the Author:	21-Jun-2020
Complete List of Authors:	Russo, Antonio; AUSL of Romagna , Dermatology Department Møllergaard, Maiken; University of Copenhagen, Immunology, Faculty of Health and Medical Sciences; Klox Technologies Ltd, R&D Pellacani, Giovanni; UniMoRe Dermatology Clinic Nisticò, Steven; Rome Torvergata University Dermatological Laser Unit Nielsen, Michael Canova Engelbrecht; Klox Technologies Ltd, R&D
Search Terms:	Dermatology, Infectious diseases
Abstract:	Acne associates with increased sebum production, bacterial colonization, and ongoing inflammation. Fluorescent light energy has reported clinical effect on acne. The complexity of acne often makes combination therapy highly beneficial. We here show that combining FLE with low-dose isotretinoin or tetracycline leads to clearance of acne without significant adverse effects.

## **Fluorescent light energy combined with systemic isotretinoin: A 52 weeks follow-up evaluating efficacy and safety in treatment of moderate-severe acne**

Antonio Russo<sup>1</sup>, Maiken Møllgaard<sup>2,3</sup>, Giovanni Pellacani<sup>4</sup>, Steven Nisticò<sup>5</sup>, and Michael Canova Engelbrecht Nielsen<sup>3</sup>

1. AUSL of Romagna Dermatology Department, Italy
2. Immunology, Faculty of Health and Medical Sciences, University of Copenhagen, 1870 Frederiksberg C, Denmark
3. Klox Technologies, 2750 Ballerup, Denmark
4. UniMoRe Dermatology Clinic, Italy
5. Department of Health Science, University of Catanzaro Magna Graecia, Italy

### **Correspondence:**

Michael Canova Engelbrecht Nielsen,  
Klox Technologies, 2750 Ballerup, Denmark,  
Email: men@kloxtech.com

Keywords: Fluorescent light energy, photobiomodulation, acne, inflammation, isotretinoin, combination therapy

### **Abstract (Max 50 words)**

Acne associates with increased sebum production, bacterial colonization, and ongoing inflammation. Fluorescent light energy has reported clinical effect on acne. The complexity of acne often makes combination therapy highly beneficial. We here show that combining FLE with low-dose isotretinoin or tetracycline leads to clearance of acne without significant adverse effects.

### **Key clinical message (Max 250 characters)**

Fluorescent light energy therapy combined with low-dose isotretinoin or tetracycline show remarkable clinical effect on 12 cases of moderate to severe acne. Treatment was considered safe, well-tolerated, and highly efficacious.

## **INTRODUCTION**

Acne is one of the most common skin conditions estimated by the Global Burden of Disease Project to display a prevalence of 9.4%, ranking it as the eighth most common diseases worldwide.<sup>1</sup> It predominantly affects adolescents and young adults affecting approximately 40-90% of this population, depending on the study methodology and definitions used.<sup>2-7</sup> Although the prevalence tends to decrease with age a substantial number of adults suffers from acne.<sup>8</sup>

Acne is defined as a chronic inflammatory skin disorder characterized by a prolonged course, a recurring pattern of flare-ups and remissions, and with a psychologic and social

impact that affects patient's quality of life.<sup>9</sup> Thus, proper treatment is essential for the patients to avoid or reduce the risk of sequelae such as scarring, emotional and psychosocial distress, occupational consequences and potential psychiatric disturbances including depression and suicide.<sup>10</sup> Although the underlying reasons for development of acne is uncertain, the disease associates with increased *Cutibacterium acnes* (*C. acnes* formerly named *Propionibacterium acnes*), and ongoing inflammation.<sup>11</sup> These factors are reflected in treatment options for acne, that target bacterial growth via antibiotics (e.g. tetracycline), sebum production by isotretinoin therapy, and inflammation by corticosteroids<sup>12-14</sup> or by fluorescent light energy (FLE) that has reported efficacy against acne possibly in part through is recently described anti-inflammatory effects.<sup>12,13,15-19</sup>

In many cases of moderate to severe acne, antibiotics and retinoids as systemic therapies are well-established.<sup>14,20</sup> However, some patients are not eligible to standard dose of isotretinoin treatment due to collateral effects, or do not reach a satisfying clearance with tetracycline or macrolides even when correctly combined with topical therapy. In these cases, low-dose regimens of oral retinoid recently demonstrated efficacy for treating acne, with superior patient satisfaction and fewer side-effects compared with standard doses.<sup>21,22</sup> Moreover, studies suggest a preventing role of a low starting dose of isotretinoin on the acute inflammatory flares that may occur during the first 3–5 weeks of treatment.<sup>23,24</sup> Additionally, systemic corticosteroids pose an adjunctive therapy option in cases of severe inflammation, to speed up clearing of lesions for approaches using low starting dose of retinoids.<sup>14,25,26</sup> Finally, optical treatments including laser and light-based therapies (photodynamic therapy (PDT), light-emitting diode (LED), and intense pulsed light (IPL)) have gained increasing interest over the last years as acne treatments<sup>27-45</sup> in an attempt to overcome the limitations associated with the standard established therapies for moderate to severe acne.<sup>46</sup>

Among these newer therapeutic approaches, the use and effectiveness of FLE therapy has been described in the treatment of acne.<sup>15,16,47,48</sup> FLE is a biophotonic platform utilizing a chromophore-containing photoconverter gel activated by a blue LED light (440-460 nm) whereby longer wavelengths of visible light (500-700 nm) energy is relayed to the cells of the skin.<sup>17,19</sup> Blue light alone has been suggested to have a cytotoxic effect on *C. acnes* likely acting on the porphyrins synthesized by the bacteria resulting in production of singlet oxygen and reactive radicals leading to membrane damage and bacterial death.<sup>49</sup> Whereas, FLE generates a unique dynamic hyperpulsed multi-wavelengths of fluorescent energy shifting the light from shorter blue wavelengths to longer wavelengths within the blue, green, yellow, orange, and red spectrum creating a complex spectrum containing several wavelengths.<sup>17</sup> This spectrum is facilitated by the Stoke's shift phenomenon, describing fluorescence as chromophores absorbing photons from (blue) light and emitting them in a lower energy state of longer wavelengths, which compared with blue light penetrate and stimulate cells and structures in the deeper layers of the skin.<sup>17,50</sup> FLE has reported efficacy on a number of (inflammatory) skin conditions, including rosacea,<sup>51,52</sup> lentiginos,<sup>53,54</sup> acneiform eruption,<sup>55</sup> acne conglobata, and hidradenitis suppurativa<sup>56</sup> as well as skin rejuvenation<sup>57</sup> and healing of acute and chronic wounds.<sup>19,58-61</sup> *In vitro* findings has reported that FLE lowers production of essential pro-inflammatory cytokines such as interleukin 6 (IL-6) and tumor necrosis factor  $\alpha$  (TNF- $\alpha$ ) in cultures of human epidermal keratinocytes and human dermal fibroblasts.<sup>17-19</sup> Finally, ongoing mechanistic studies suggest that FLE directly modify mitochondrial morphology and function.<sup>18,62</sup>

We hypothesize that targeting several aspects of acne by initially lowering sebum production by low-dose isotretinoin treatment<sup>63,64</sup> or hampering bacterial growth by tetracycline in combination with the anti-inflammatory and homeostasis promoting properties of FLE will clear acne and normalize the skin longterm.<sup>15-17,19,62</sup> This combination will initially target several pathways associated with acne and longer term FLE therapy will reprogram and balance skin cells and conditions ensuring no remission of disease. The combination of FLE treatment with systemic drugs has not yet been established. We recently compiled the experiences of seven FLE-experienced doctors on their off label use of combining FLE and low-dose isotretinoin therapy suggesting new applications for treatment of acne.<sup>65</sup> We suggest that the direct anti-inflammatory effects of FLE combined with administration of the well-described systemic anti-acne therapeutics, isotretinoin or tetracycline in low-dose will clear acne and normalize the skin ensuring longterm clearance without severe adverse effects. Our objective was to test and describe the efficacy and safety of the combination of FLE therapy with low-dose isotretinoin or tetracycline in cases of moderate to severe acne.

## **MATERIALS AND METHODS**

### **Patients**

This trial represents a series of collected cases of patients treated for moderate to severe inflammatory facial acne. Enrolled patients were overall ineligible to standard dose of retinoids for health or personal reasons. A urine or blood pregnancy test was required for female subjects at the screening, baseline and then every 4 weeks for all the period of the study. Detailed criteria for inclusion and exclusion are listed in Table I.

Acne severity was graded according to the Investigator's Global Assessment (IGA) scale (Table II)<sup>66-68</sup>, by the treating physician. In total 12 cases were included, seven male and five female patients. Baseline grading ensured that 50% of the patients presented with moderate (IGA 3) and 50% with severe (IGA 4) acne (Table III).

### **FLE Treatment**

Patients were treated with FLE according to the biophotonic treatment protocol. A thin layer (2 mm) of a topical photoconverter gel was applied to the face with the eyes protected by ocular shields. The gel was subsequently illuminated by a multi-LED lamp delivering non-coherent blue light with a power density of 150 mW/cm<sup>2</sup> and an optimized peak wavelength of 440-460nm. Illumination was done at a distance of 5 cm from the skin surface for a duration of 9 min.<sup>15-17,57</sup>

After each session of illumination, the exhausted photoconverter gel was removed<sup>15,16</sup>, and skin moisturizing products for acneic skin was applied. Patients were treated with double FLE treatments (two treatments with a 2 hour break between treatments) once a week for 6 weeks (total of 12 FLE treatments). Double FLE treatments were repeated after 6 and 1 months.

### **Systemic Treatment**

Patients were started in systemic treatment on day one of FLE treatment. The oral dose of isotretinoin was 5 mg/day and tetracycline (Lymecycline) 300 mg/day. Tetracycline was

preferred to doxycycline because of its less photosensitizing effect.<sup>69</sup> The patients were prescribed to take retinoids regularly throughout the study. Tetracycline was stopped after 12 weeks while isotretinoin was continued until acceptable clearance was obtained for each case. 9 patients (5 males, 2 with IGA 4 and 3 with IGA 3 and 4 females with IGA 4) started isotretinoin 5 mg/day and 3 patients (2 males and 1 female both with IGA 3) tetracycline (Lymecycline) 300 mg/day (Table III). Finally, patients were prescribed a cleaning soap for greasy skin and a moisturizing gel for acneic skin with isomerate saccharide and nicotinamide and a lip balm for patients taking retinoids. Patients were advised to avoid or minimize UV-exposure or use UVA and UVB high protection, especially during the summer period and for patients taking isotretinoin.

### **Efficacy evaluation**

Efficacy evaluations at week 6, 12, 33 and 52 were performed using the IGA scale (Table II and III). IGA assessment throughout the trial was performed as open-end analysis by the treating physician. Furthermore, patients rated their satisfaction according to improvement in overall appearance and texture on a 5-point Likert scale (very dissatisfied, dissatisfied, no opinion, satisfied and very satisfied) at the end of the study.

### **Safety evaluation**

At the end of each FLE treatment session patients received an assessment questionnaire to report side-effects, graded on a scale defined as mild, tolerable, unpleasant, or intolerable.

### **Ethics Statement**

Since the patients were treated with existing, approved therapies for acne, no approval from ethics committees was needed. Informed written consent was provided by patients for the use of their photos.

## **RESULTS**

Therapy combinations were tailored according to the individual patient's response to previous treatments, health condition, and current wishes. In half of the cases, patients were not eligible to standard doses of isotretinoin due to previous discontinued therapy caused by severe adverse effects, including dryness of skin, elevated levels of creatine phosphokinase (CPK) or transaminase, worsening of symptoms, or preceding disease history (Figure 1A-D). Furthermore, most patients had previously been treated with tetracycline and topical therapeutics without effect. These patients were in this trial treated with FLE in combination with low-dose isotretinoin alone or for some female cases together with contraceptives. Substantial improvements in acne symptoms were observed in all six patients already at week 6 after treatment was initiated with further gradual clearance throughout the trial and complete clearance at week 52 (Figure 1A-D).

A group of non-responders to tetracycline and topical treatments was treated with FLE in combination with low-dose isotretinoin (Figure 2 and 3A). In these patients a similar gradual

clearance was seen throughout the treatment and observation time. Especially a marked progressive reduction in inflammation was observed (Figure 2 and 3A).

Finally, three patients with moderate acne symptoms were treated with FLE combined with tetracycline. For these patients previous treatment using topical or standard dose tetracycline or isotretinoin regimes failed. Although substantial improvements were observed for all three patients, few papules and comedones remained and complete clearance was not obtained (Figure 3B-D).

Taken together, all patients showed substantial improvements in the clinical appearance of the skin already at week 6 after treatment was initiated (Figure 4A). In 50% of the cases, patients showed a marked enhancement quantified by a 2-grade improvement according to the IGA scale, whereas the remaining 50% presented with a 1-grade decrease according to the IGA score (Table III). At the week 12 evaluation, 75% of patients showed a reduction in clinical severity to IGA 1. The remaining 25%, showed improvements corresponding to 1- to 2-grade IGA reduction although maintaining IGA scores of 2-3. Interestingly, at the evaluation at week 33 and 52 patients treated with FLE in combination with isotretinoin reached and maintained an IGA score of 0 at week 33 and 52, whereas the three patients treated with FLE combined with tetracycline presented an IGA score of 1 (Table III).

At the final evaluation at week 52, patients evaluated satisfaction with the clinical outcome and the treatment as a whole. All patients reported high satisfaction rates with the treatment results. Overall, 75% of subjects were very satisfied and 25% satisfied with the treatment outcome (Figure 4B). Thus, we found a substantial association between IGA-rated improvement and patient satisfaction.

Adverse effects related to the treatments were assessed after each FLE session by the patients evaluating and reporting. Overall, no severe or intolerable adverse effects were reported (Figure 4C) and no patients discontinued the study. In line with previous clinical studies,<sup>15,16</sup> a few patients reported that FLE treatment induced transient erythema (lasting no more than 36 hours), temporary skin hyperpigmentation or a slight sensation of burning during the session (Figure 4C). The most reported side-effects related to the systemic therapy, including dryness of skin and mucosae in patients taking isotretinoin and transient abdominal swelling (lasting a few days) in patients on tetracycline (Figure 4C).

## DISCUSSION

Acne is a common skin condition usually characterized by a prolonged course, a recurring pattern of flare-ups and remissions, with a psychologic and social impact, that affects the individual's quality of life.<sup>1-7,9</sup> Thus, proper treatment is imperative for these patients. A central role of antibiotics and retinoids as systemic therapies for acne is well established despite a challenged safety profile, that for many lead to significant adverse effects often resulting in ceased treatment.<sup>14,20,46,69</sup> Therefore, low-dose regimens of oral retinoids or antibiotics combined with corticosteroids or other anti-inflammatory therapies represent an interesting alternative approach.<sup>14,21-26</sup> Furthermore, other viable and more recent options to overcome the limitations associated with standard established acne therapies,<sup>20,46</sup> are light-based therapy such as FLE with previous clinical evaluation reporting improvement of at least one IGA grade by week 12 for 88,8% of patients treated for moderate to severe acne.<sup>15</sup> Acne is a highly complex and multifactorial skin condition, which challenge

treatment. It is unknown why some patients respond less pronounced to FLE treatment or tetracycline alone or why only some patients experience severe adverse effect of standard dose isotretinoin therapy. However, combination therapies are often advantageous for complex skin diseases such as acne and rosacea,<sup>12,70</sup> leading to our hypothesis that targeting several acne infliction factors by combining FLE with low-dose isotretinoin or tetracycline treatment is highly advantageous. Our objective was therefore to describe the efficacy and safety of the combination of FLE with low-dose systemic drugs, isotretinoin or tetracycline in treatment of moderate to severe acne.

Efficacy evaluation was performed by IGA grading severity and improvements at week 6, 12, 33 and 52. We found that at the first assessment, 6 weeks after treatment was initiated, all patients showed improvements of at least 1 IGA grade in their clinical skin conditions, while 50% showed 2 IGA grades improvement. This fast response can sometimes be obtained in patients treated with standard dose of tetracycline,<sup>71</sup> but is unlikely to be explained by the low-dose regimen of tetracycline or isotretinoin used in this trial, suggesting a positive additive effect of FLE. Moreover, efficacy evaluation at week 12 revealed that as much as 75% of the treated cases dropped to an IGA grade of 1, which could likely not be ascribed to low-dose systemic treatment alone, further substantiating the positive effect of the tested FLE-combination therapy. All patients treated with isotretinoin reached and maintained an IGA grade of 0 at weeks 33 and 52. The three cases treated with tetracycline; however, obtained not more than a drop in IGA grade to 1 at weeks 33 and 52. This further corroborates the efficacy of combining low-dose systemic treatment with FLE therapy, although seemingly more efficient when combined with isotretinoin compared with tetracycline. Although, more cases are needed to further assess these considerations, they are in line with or recent and imminent observations.<sup>65</sup>

Symptoms of acne is known to fluctuate and worsening in beginning of treatment is a common side-effect, often requiring long-term systemic therapy to obtain and maintain clearance.<sup>11</sup> This has many disadvantages, for standard dose isotretinoin this associates with continuous risk of adverse effects such as increased CPK levels and xerosis, whereas tetracycline risk development of antibiotic resistance.<sup>72</sup> Interestingly, we found that remarkable improvements of the disease was obtained fast and persisted throughout the evaluation period with only one course of antibiotic treatment necessary, besides follow-up FLE sessions at week 33 and 52. The clinical, cellular and molecular pathways targeted and modulated by FLE is currently under investigation. Results so far indicate that FLE modulate activity and function of several skin cells as well as directly target bacterial viability,<sup>17-19,49,62</sup> suggesting that FLE improve acne symptoms by targeting several aspects of the disease. We speculate that the combined treatment of moderate-severe acne by FLE, targeting inflammation and likely other aspects of this complex condition in combination with initial isotretinoin that lower sebum production or tetracycline directly killing *C. acnes* bacteria lay the basis for consistent normalization of the skin.

Finally, all 12 enrolled patients completed the therapy and were satisfied with the outcome, treatment was well-tolerated overall, and no severe adverse effects were reported. In general, patients experienced fast (within few weeks) improvement of their inflammatory acne skin conditions with redness reduction, edema decreasing and a general improvement of skin appearance. Low-dose isotretinoin treatment was maintained for some patients, evaluated individually according to obtaining the desired clearance, but no intolerable adverse effects were reported in relation to this. Our results support the combination of FLE treatment with tetracyclines or low-dose isotretinoin in moderate to severe acne. Although

both isotretinoin and tetracycline are potential photosensitizing drugs,<sup>11,72</sup> their use according to our study protocol, did not negatively interfere with FLEtreatment, but seemingly enhance its efficacy in a safe and long-term manner.

#### **ACKNOWLEDGEMENTS**

We acknowledge the Innovation Fund Denmark for Postdoc stipend to MM (#8054-00028B).

#### **CONFLICTS OF INTEREST**

MM and MCEN are employees of Klox Technologies.

#### **AUTHOR CONTRIBUTIONS**

AR, GP, and SN: study design AR and SN: patient selection and clinical assessment. AR, GP, SN, MM, and MCEN: drafting and writing manuscript. All authors have revised and reviewed manuscript and has approved the final version.

#### **CONSENT**

Written informed consent was acquired for all patients.

#### **REFERENCES**

- Tan JK, Bhate K. A global perspective on the epidemiology of acne. *Br J Dermatol*. 2015;172 Suppl 1:3-12.
- Wolkenstein P, Machovcova A, Szepietowski JC, Tennstedt D, Veraldi S, Delarue A. Acne prevalence and associations with lifestyle: a cross-sectional online survey of adolescents/young adults in 7 European countries. *J Eur Acad Dermatol Venereol*. 2018;32(2):298-306.
- Ghods SZ, Orawa H, Zouboulis CC. Prevalence, severity, and severity risk factors of acne in high school pupils: a community-based study. *J Invest Dermatol*. 2009;129(9):2136-2141.
- Karciauskiene J, Valiukeviciene S, Gollnick H, Stang A. The prevalence and risk factors of adolescent acne among schoolchildren in Lithuania: a cross-sectional study. *J Eur Acad Dermatol Venereol*. 2014;28(6):733-740.
- Walker N, Lewis-Jones MS. Quality of life and acne in Scottish adolescent schoolchildren: use of the Children's Dermatology Life Quality Index (CDLQI) and the Cardiff Acne Disability Index (CADi). *J Eur Acad Dermatol Venereol*. 2006;20(1):45-50.
- Wu TQ, Mei SQ, Zhang JX, et al. Prevalence and risk factors of facial acne vulgaris among Chinese adolescents. *Int J Adolesc Med Health*. 2007;19(4):407-412.
- Hanisah A, Omar K, Shah SA. Prevalence of acne and its impact on the quality of life in school-aged adolescents in Malaysia. *J Prim Health Care*. 2009;1(1):20-25.
- Poli F, Dreno B, Verschoore M. An epidemiological study of acne in female adults: results of a survey conducted in France. *J Eur Acad Dermatol Venereol*. 2001;15(6):541-545.
- Thiboutot D, Gollnick H, Bettoli V, et al. New insights into the management of acne: an update from the Global Alliance to Improve Outcomes in Acne group. *J Am Acad Dermatol*. 2009;60(5 Suppl):S1-50.
- Prevost N, English JC. Isotretinoin: update on controversial issues. *J Pediatr Adolesc Gynecol*. 2013;26(5):290-293.



Williams HC, Dellavalle RP, Garner S. Acne vulgaris. *Lancet (London, England)*. 2012;379(9813):361-372.

Roman CJ, Cifu AS, Stein SL. Management of Acne Vulgaris. *Jama*. 2016;316(13):1402-1403.

Melnik BC. Apoptosis May Explain the Pharmacological Mode of Action and Adverse Effects of Isotretinoin, Including Teratogenicity. *Acta Derm Venereol*. 2017;97(2):173-181.

Thiboutot DM, Dreno B, Abanmi A, et al. Practical management of acne for clinicians: An international consensus from the Global Alliance to Improve Outcomes in Acne. *J Am Acad Dermatol*. 2018;78(2 Suppl 1):S1-S23.e21.

Antoniou C, Dessinioti C, Sotiriadis D, et al. A multicenter, randomized, split-face clinical trial evaluating the efficacy and safety of chromophore gel-assisted blue light phototherapy for the treatment of acne. *Int J Dermatol*. 2016;55(12):1321-1328.

Nikolis A, Fauverghe S, Scapagnini G, et al. An extension of a multicenter, randomized, split-face clinical trial evaluating the efficacy and safety of chromophore gel-assisted blue light phototherapy for the treatment of acne. *Int J Dermatol*. 2018;57(1):94-103.

Edge D, Mellergaard M, Dam-Hansen C, et al. Fluorescent light energy: the future for treating inflammatory skin conditions? *The Journal of Clinical and Aesthetic Dermatology*. 2019.

Zago M, Dehghani M, Jaworska J, et al. *Fluorescent light energy in wound healing: when is a photon something more?* Vol 11221: SPIE; 2020.

Scapagnini G, Marchegiani A, Rossi G, et al. *Management of all three phases of wound healing through the induction of fluorescence biomodulation using fluorescence light energy*. Vol 10863: SPIE; 2019.

Nast A, Dreno B, Bettoli V, et al. European evidence-based (S3) guideline for the treatment of acne - update 2016 - short version. *J Eur Acad Dermatol Venereol*. 2016;30(8):1261-1268.

Lee JW, Yoo KH, Park KY, et al. Effectiveness of conventional, low-dose and intermittent oral isotretinoin in the treatment of acne: a randomized, controlled comparative study. *Br J Dermatol*. 2011;164(6):1369-1375.

Van TLT, Minh PN, Thuy PTT, et al. Efficacy of Oral Low-Dose Isotretinoin in the Treatment of Acne Vulgaris in Vietnam. *Open Access Maced J Med Sci*. 2019;7(2):279-282.

Lehucher-Ceyrac D, de La Salmoniere P, Chastang C, Morel P. Predictive factors for failure of isotretinoin treatment in acne patients: results from a cohort of 237 patients. *Dermatology*. 1999;198(3):278-283.

Chivot M. [Acne flare-up and deterioration with oral isotretinoin]. *Ann Dermatol Venereol*. 2001;128(3 Pt 1):224-228.

Mehra T, Borelli C, Burgdorf W, Rocken M, Schaller M. Treatment of severe acne with low-dose isotretinoin. *Acta Derm Venereol*. 2012;92(3):247-248.

Allison MA, Dunn CL, Person DA. Acne fulminans treated with isotretinoin and "pulse" corticosteroids. *Pediatr Dermatol*. 1997;14(1):39-42.

Katsambas A, Dessinioti C. New and emerging treatments in dermatology: acne. *Dermatol Ther*. 2008;21(2):86-95.

Hamilton FL, Car J, Lyons C, Car M, Layton A, Majeed A. Laser and other light therapies for the treatment of acne vulgaris: systematic review. *Br J Dermatol*. 2009;160(6):1273-1285.

Mariwalla K, Rohrer TE. Use of lasers and light-based therapies for treatment of acne vulgaris. *Lasers in surgery and medicine*. 2005;37(5):333-342.

Haedersdal M, Togsverd-Bo K, Wulf HC. Evidence-based review of lasers, light sources and photodynamic therapy in the treatment of acne vulgaris. *J Eur Acad Dermatol Venereol*. 2008;22(3):267-278.

Barbaric J, Abbott R, Posadzki P, et al. Light therapies for acne: abridged Cochrane systematic review including GRADE assessments. *Br J Dermatol*. 2018;178(1):61-75.

Sadick NS, Cardona A. Laser treatment for facial acne scars: A review. *J Cosmet Laser Ther*. 2018;20(7-8):424-435.

Wiznia LE, Stevenson ML, Nagler AR. Laser treatments of active acne. *Lasers in medical science*. 2017;32(7):1647-1658.

Alexiades M. Laser and light-based treatments of acne and acne scarring. *Clin Dermatol*. 2017;35(2):183-189.

Gold MH, Goldberg DJ, Nestor MS. Current treatments of acne: Medications, lights, lasers, and a novel 650-nm 1064-nm Nd: YAG laser. *J Cosmet Dermatol*. 2017;16(3):303-318.

Tong LX, Brauer JA. Lasers, Light, and the Treatment of Acne: A Comprehensive Review of the Literature. *J Drugs Dermatol*. 2017;16(11):1095-1102.

Marson JW, Baldwin HE. An Overview of Acne Therapy, Part 1: Topical therapy, Oral Antibiotics, Laser and Light Therapy, and Dietary Interventions. *Dermatol Clin*. 2019;37(2):183-193.

Perper M, Tsatalis J, Eber AE, Cervantes J, Nouri K. Lasers in the treatment of acne. *G Ital Dermatol Venereol*. 2017;152(4):360-372.

Posadzki P, Car J. Light Therapies for Acne. *JAMA Dermatol*. 2018;154(5):597-598.

Scott AM, Stehlik P, Clark J, et al. Blue-Light Therapy for Acne Vulgaris: A Systematic Review and Meta-Analysis. *Ann Fam Med*. 2019;17(6):545-553.

Salavastru C, Tiplica GS, Branisteanu DE, Fritz K. [Light-based inflammatory acne treatments]. *Hautarzt*. 2018;69(1):27-34.

Boen M, Brownell J, Patel P, Tsoukas MM. The Role of Photodynamic Therapy in Acne: An Evidence-Based Review. *Am J Clin Dermatol*. 2017;18(3):311-321.

Riddle CC, Terrell SN, Menser MB, Aires DJ, Schweiger ES. A review of photodynamic therapy (PDT) for the treatment of acne vulgaris. *J Drugs Dermatol*. 2009;8(11):1010-1019.

Zheng W, Wu Y, Xu X, Gao X, Chen HD, Li Y. Evidence-based review of photodynamic therapy in the treatment of acne. *Eur J Dermatol*. 2014;24(4):444-456.

Pei S, Inamadar AC, Adya KA, Tsoukas MM. Light-based therapies in acne treatment. *Indian Dermatol Online J*. 2015;6(3):145-157.

Nast A, Dreno B, Bettoli V, et al. European evidence-based (S3) guidelines for the treatment of acne. *J Eur Acad Dermatol Venereol*. 2012;26 Suppl 1:1-29.

Jalili A. *Chromophore gel-assisted phototherapy: A novel and promising photobiomodulation therapy for facial inflammatory skin diseases and skin aging*. Vol 112018.

Jalili A. Chromophore gel-assisted phototherapy. *Journal für Ästhetische Chirurgie*. 2019;12(1):1-5.

Boyd JM, Lewis KA, Mohammed N, et al. Propionibacterium acnes susceptibility to low-level 449 nm blue light photobiomodulation. *Lasers in surgery and medicine*. 2019;51(8):727-734.

Hamblin MR. Mechanisms and applications of the anti-inflammatory effects of photobiomodulation. *AIMS biophysics*. 2017;4(3):337-361.

Braun SA, Gerber PA. A photoconverter gel-assisted blue light therapy for the treatment of rosacea. *Int J Dermatol*. 2017;56(12):1489-1490.

Sannino M, Lodi G, Dethlefsen MW, Nistico SP, Cannarozzo G, Nielsen MCE. Fluorescent light energy: Treating rosacea subtypes 1, 2, and 3. *Clin Case Rep*. 2018;6(12):2385-2390.

Gerber PA, Scarcella G, Edge D, Nielsen MCE. Biophotonic pretreatment enhances the targeting of senile lentigines with a 694 nm QS-ruby laser. *Photodermatol Photoimmunol Photomed*. 2019.

Scarcella G, Dethlefsen MW, Nielsen MCE. Treatment of solar lentigines using a combination of picosecond laser and biophotonic treatment. *Clin Case Rep.* 2018;6(9):1868-1870.

Mahendran A, Wong XL, Kao S, Sebaratnam DF. Treatment of erlotinib-induced acneiform eruption with chromophore gel-assisted phototherapy. *Photodermatol Photoimmunol Photomed.* 2019;35(3):190-192.

Koceva I, Rummelein B, Gerber PA, Edge D, Nielsen MCE. Fluorescent light energy: A new therapeutic approach to effectively treating acne conglobata and hidradenitis suppurativa. *Clin Case Rep.* 2019;7(9):1769-1772.

Nikolis A, Bernstein S, Kinney B, Scuderi N, Rastogi S, Sampalis JS. A randomized, placebo-controlled, single-blinded, split-faced clinical trial evaluating the efficacy and safety of KLOX-001 gel formulation with KLOX light-emitting diode light on facial rejuvenation. *Clin Cosmet Investig Dermatol.* 2016;9:115-125.

Romanelli M, Piaggese A, Scapagnini G, et al. Evaluation of fluorescence biomodulation in the real-life management of chronic wounds: the EUREKA trial. *J Wound Care.* 2018;27(11):744-753.

Fogacci T, Cattin F, Semprini G, Frisoni G, Fabiocchi L, Samorani D. The use of chromophore gel-assisted blue light phototherapy (Lumiheal) for the treatment of surgical site infections in breast surgery. *Breast J.* 2018;24(6):1135.

M Møllergaard SF, C Scarpa, VL Pozner, S Skov, L Hebert, M Nielsen, F Bassetto, and L Tétou Evaluation of Fluorescent Light Energy for the Treatment of Acute Second-degree Burns and Scars. *article submitted to Military Medicine* Jan 2020.

61. Ding J MM, Kwana P, Edge D, Ma Z, Zhu Z, Hebert L, Alrobaiea S, Iwasaki T, Nielsen MCE, and Tredget EE. Fluorescence light energy (FLE) accelerates wound closure and re-epithelialization in a skin graft mouse model. *Submitted to Frontiers in Bioengineering and Biotechnology.* 2020.

62. Ferroni L, Zago M, Patergnani S, et al. Fluorescent Light Energy (FLE) Acts on Mitochondrial Physiology Improving Wound Healing. *J Clin Med.* 2020;9(2).

63. Bettoli V, Guerra-Tapia A, Herane MI, Piquero-Martín J. Challenges and Solutions in Oral Isotretinoin in Acne: Reflections on 35 Years of Experience. *Clin Cosmet Investig Dermatol.* 2019;12:943-951.

64. Layton A. The use of isotretinoin in acne. *Dermatoendocrinol.* 2009;1(3):162-169.

65. Møllergaard M, Eguren, C, Romero, D, Bordignon, M, Darwich, E, Pauletti, L, Guareschi, ME, Ricart, JM, Nielsen, MCE. Consensus-based alternative regimes for treating acne and rosacea using fluorescent light energy with low-dose isotretinoin. *Under review: Journal of Drugs in Dermatology.* 2020.

Guidance for Industry; Acne Vulgaris: Developing Drugs for Treatment (Draft Guidance). <http://www.fda.gov/downloads/Drugs/GuidanceComplianceRegulatoryInformation/Guidances/UCM071292.pdf>2005:1-14.

Methicillin-resistant Staphylococcus aureus. *Nature reviews Disease primers.* 2018;4:18034.

Tan JK, Tang J, Fung K, et al. Development and validation of a comprehensive acne severity scale. *J Cutan Med Surg.* 2007;11(6):211-216.

Dreno B, Bettoli V, Ochsendorf F, Layton A, Mobacken H, Degreef H. European recommendations on the use of oral antibiotics for acne. *Eur J Dermatol.* 2004;14(6):391-399.

Del Rosso JQ, Thiboutot D, Gallo R, et al. Consensus recommendations from the American Acne & Rosacea Society on the management of rosacea, part 3: a status report on systemic therapies. *Cutis.* 2014;93(1):18-28.

Simonart T, Dramaix M, De Maertelaer V. Efficacy of tetracyclines in the treatment of acne vulgaris: a review. *Br J Dermatol.* 2008;158(2):208-216.

Chon SY, Doan HQ, Mays RM, Singh SM, Gordon RA, Tyring SK. Antibiotic overuse and resistance in dermatology. *Dermatol Ther.* 2012;25(1):55-69.

## FIGURE LEGENDS

### Figure 1. FLE treatment combined with low-dose isotretinoin

**A)** A 28 year old female patient presenting with baseline acne severity of IGA 4. The patient was not eligible to standard doses of isotretinoin, due to previous discontinued therapy due to severe dryness of the skin, and previous tetracycline treatment did not improve the acne. The patient was started on low-dose isotretinoin and drospirenone/ethinyl estradiol (OCP) combined with FLE treatment. **B)** A 27 year old female patient presenting with baseline acne severity of IGA 4, previously treated with topical treatment and tetracycline without effect. Due to the patient's history of pseudotumor cerebri, the patient was not eligible to start standard doses of tetracycline or isotretinoin and was started in low-dose isotretinoin and levonogestrel (IUD) combined with FLE treatment. **C)** A 18 year old male patient presenting with baseline acne severity of IGA 4. The patient was previously treated with topical treatment, tetracycline without effect, and discontinued isotretinoin due to elevated levels of creatine phosphokinase (CPK), and thereby not eligible to standard dose of isotretinoin. The patient was started in low-dose isotretinoin combined with FLE treatment. **D)** A 20 year old female patient presenting with baseline acne severity of IGA 4, previously undergoing topical therapy without effect, now wishing fast response before summertime. The patient was started in isotretinoin combined with FLE treatment. Appearance of the skin as presented at each evaluation; baseline (upper row), week 6 (second row from top), week 12 (third row from top), week 33 (fourth row from top), and week 52 (bottom row).

### Figure 2. FLE treatment combined with low-dose isotretinoin

**A)** A 20 year old male patient presenting with baseline acne severity of IGA 4, previously undergoing topical and tetracycline therapy without effect, now wishing fast response before summertime. The patient was started in isotretinoin combined with FLE treatment. **B)** A 18 year old male patient presenting with baseline acne severity of IGA 3. The patient was previously treated with topical treatment, tetracycline without effect, and discontinued isotretinoin due to elevated levels of CPK, and thereby not eligible to standard dose of isotretinoin. The patient was started in low-dose isotretinoin combined with FLE treatment. **C)** A 20 year old female patient presenting with baseline acne severity of IGA 4. The patient was previously started on standard dose of isotretinoin, which was discontinued due to non-tolerated initial worsening of her acne. Not being eligible to standard doses of isotretinoin the patient was started on low-dose isotretinoin and OCP combined with FLE treatment. **D)** A 18 year old male patient presenting with baseline acne severity of IGA 3. The patient was previously treated with topical treatment, tetracycline without effect, and discontinued isotretinoin due to elevated levels of CPK and transaminase, and thereby not eligible to standard dose of isotretinoin. The patient was started in low-dose isotretinoin combined with FLE treatment. Appearance of the skin as presented at each evaluation; baseline (upper row), week 6 (second row from top), week 12 (third row from top), week 33 (fourth row from top), and week 52 (bottom row).

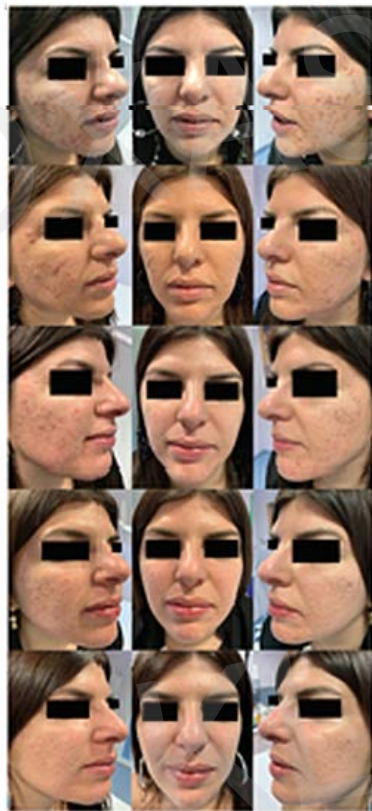### **Figure 3. FLE treatment combined with low-dose tetracycline**

**A)** A 19 year old male patient presenting with baseline acne severity of IGA 3. The patient was previously treated with topical treatment and tetracycline without effect. Wishing fast response and unable to meet frequent blood analysis required for standard dose of isotretinoin therapy. The patient was started in low-dose isotretinoin combined with FLE treatment. **B)** A 19 year old male patient presenting with baseline acne severity of IGA 3, previously undergoing topical and tetracycline therapy without effect and discontinued isotretinoin treatment due to adverse effects. The patient was started on tetracycline combined with FLE treatment. **C)** A 17 year old male patient presenting with baseline acne severity of IGA 3. The patient was previously treated with topical treatment without effect. Now wishing a fast response, the patient was started on tetracycline combined with FLE treatment. **D)** A 24 year old female patient presenting with baseline acne severity of IGA 3. The patient was previously treated with topical treatment, tetracycline with norelgestromin/ethinylestradiol (Evra), without effect. The patient was started on tetracycline and norelgestromin/ethinyl estradiol (BCP) combined with FLE treatment. Appearance of the skin as presented at each evaluation; baseline (upper row), week 6 (second row from top), week 12 (third row from top), week 33 (fourth row from top), and week 52 (bottom row).

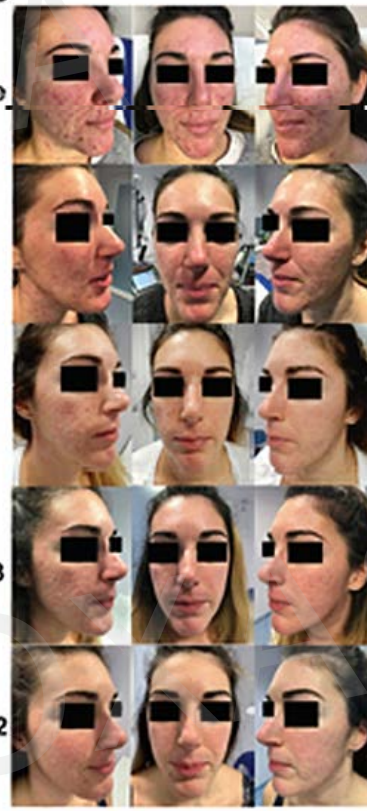### **Figure 4. Assessment of efficacy, patient satisfaction, and adverse effects**

**A)** Efficacy of treatment was determined at week 6, 12, 33, and 52 after treatment was initiated by IGA grading. **B)** Patient satisfaction was assessed at the final evaluation at week 52 by grading satisfaction on a 5-point Likert scale (very dissatisfied, dissatisfied, no opinion, satisfied and very satisfied). **C)** Treatment associated adverse effects were reported by the patients after each FLE treatment session through use of a questionnaire grading side-effects according to experienced as mild, tolerable, unpleasant, or intolerable.

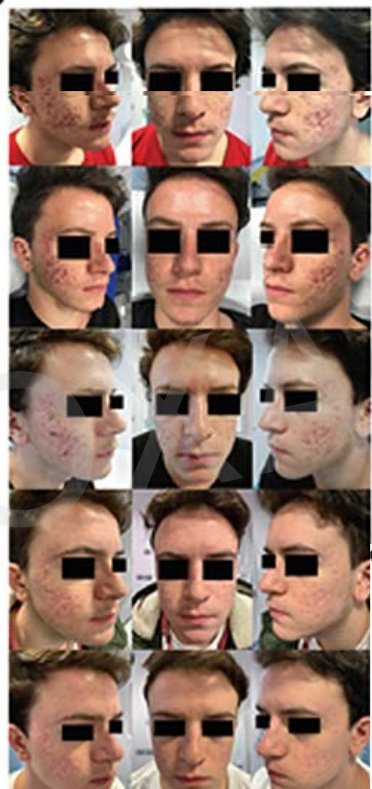
Figure 1 A



B



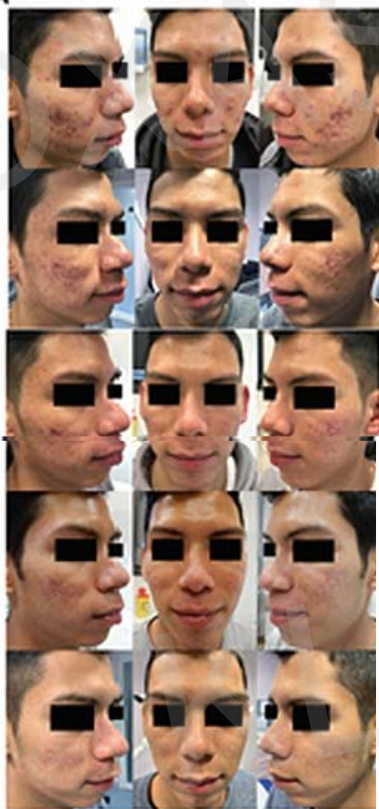
C



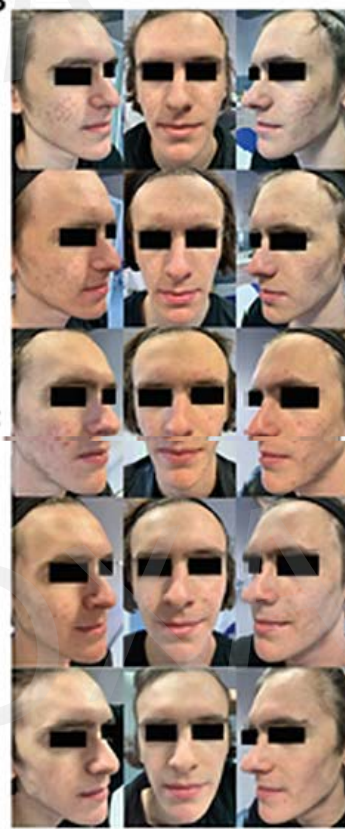D



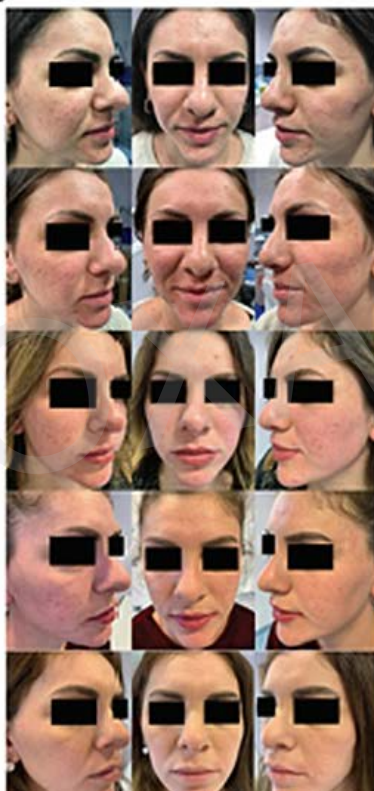Figure 2 A



B



C



D

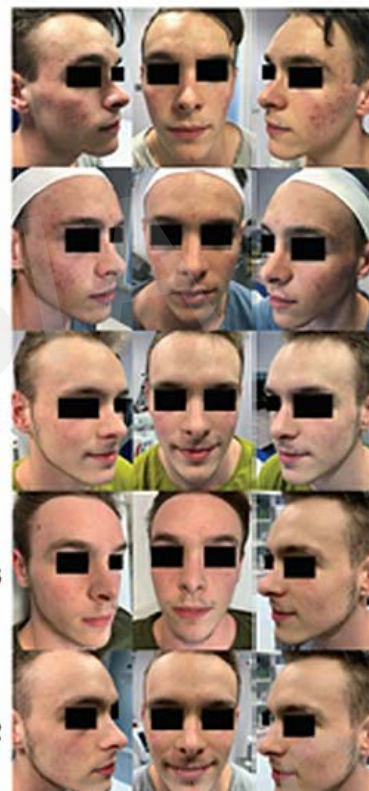
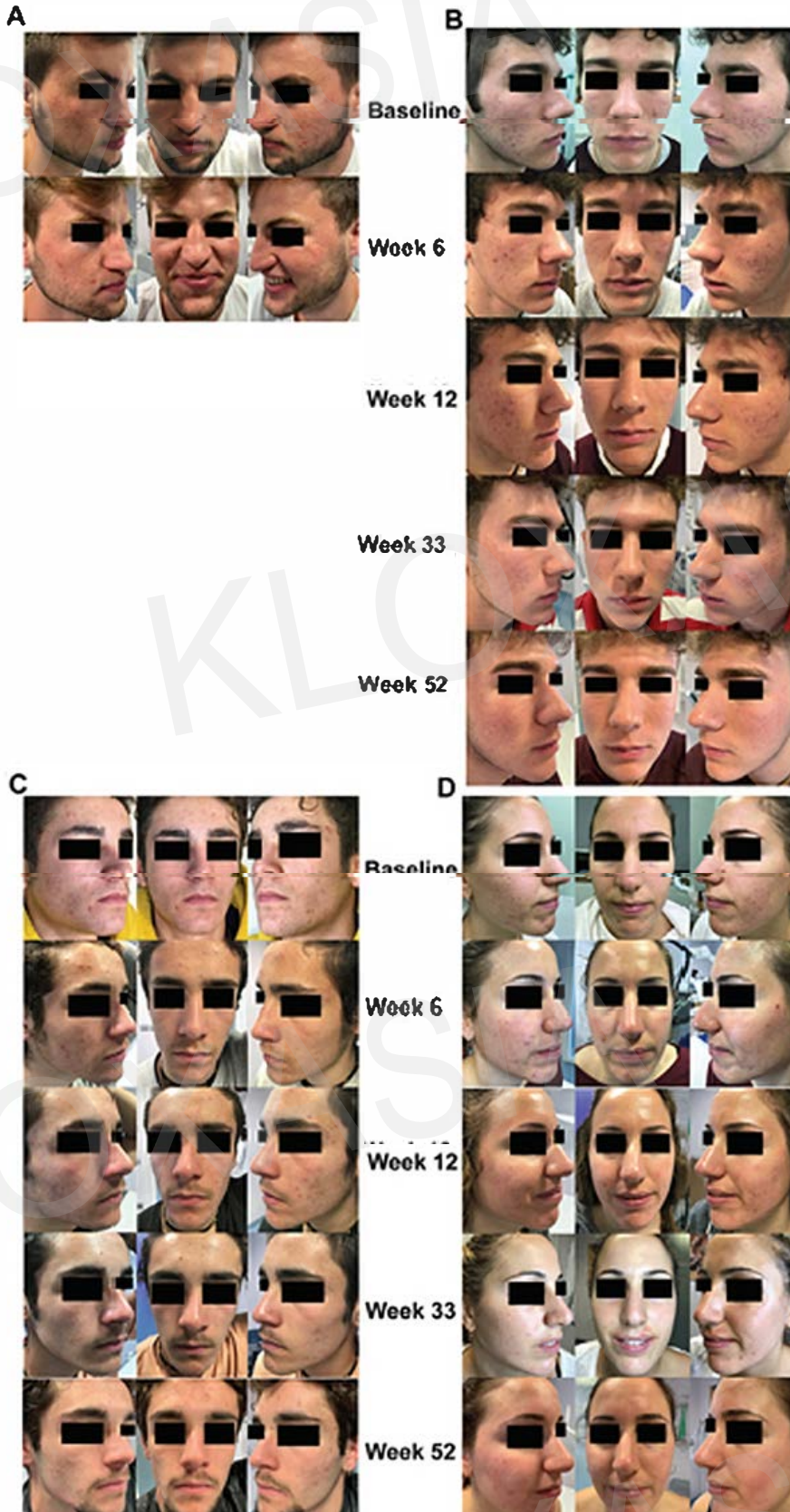
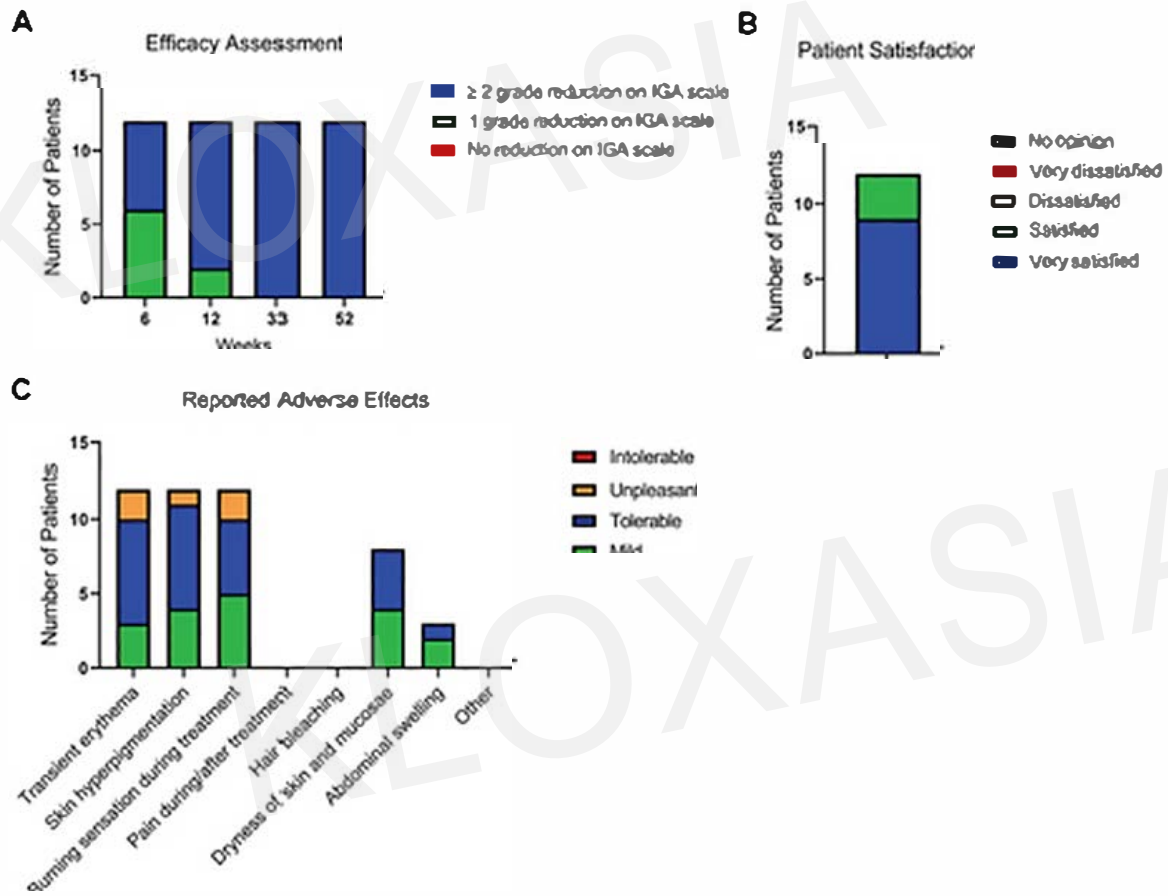


Figure 3





**Figure 4**



## TABLES

**Table I: Criteria for including patients**

Inclusion	Exclusion
IGA 3-4 (severe papulo-pustular or conglobate acne)	Isotretinoin or tetracyclines systemic treatment within last 12 months
Partial/absent response to previous acne treatments	Topical retinoid treatment within last 6 months
Ineligibility to standard dose of retinoids	Use of photosensitivity-inducing drugs
Refusing standard dosage therapy with isotretinoin due to risk of collateral effects	Use of corticosteroids within last 6 months
Anamnestic discontinuation of standard dosage therapy with systemic retinoids due to unsustainable side-effects	Pregnancy or breast-feeding
No clearance with combined tetracycline and topical therapy	

**Table II: Investigator's Global Assessment (IGA) of acne severity**

<b>Grade</b>	<b>Severity</b>	<b>Symptoms</b>
0	Clear	Residual hyperpigmentation and erythema may be present
1	Almost Clear	A few scattered comedones and a few small papules
2	Mild	Easily recognisable; less than half the face is involved. Some comedones and some papules and pustules
3	Moderate	More than half the face is involved. Many comedones, papules and pustules. One nodule may be present
4	Severe	Entire face is involved, covered with comedones, numerous papules and pustules, and few nodules and cysts

**Investigator Global Assessment (IGA) of acne severity**<sup>43</sup>

**Table III: Summary data table**

Case	Age	Gender	Previous treatment	Systemic treatment		IGA W0	IGA W6	IGA W12	IGA W33	IGA W52
1	28	F	Topical TET and ISO	ISO 5mg/day	OCP	4	3	1	0	0
2	27	F	Topical TET	ISO 5mg/day	Levonogestrel IUD	4	2	2	0	0
3	18	M	Topical TET and ISO	ISO 5mg/day		4	3	3	0	0
4	19	M	Topical TET	ISO 5mg/day		3	2	1	0	0
5	20	F	Topical	ISO 5mg/day		4	2	1	0	0
6	19	M	Topical TET and ISO	TET 300mg/day,12wks		3	2	1	1	1
7	18	M	Topical TET and ISO	ISO 5mg/day		3	1	1	0	0
8	20	M	Topical TET	ISO 5mg/day		4	2	1	0	0
9	20	F	Topical TET and ISO	ISO 5mg/day	OCP	4	2	1	0	0
10	24	F	Topical TET and Evra	TET 300mg/day,12wks	BCP	3	1	1	1	1
11	18	M	Topical TET ISO	ISO 5mg/day		3	2	2	0	0
12	17	M	Topical	TET 300mg/day,12wks		3	2	1	1	1

ISO: Isotretinoin; TET: Tetracycline; OCP: Dienogest/ethinyl estradiol; IUD: Intrauterine device; BCP: Norelgestromin/ethinyl estradiol